

Serious form of the coronary artery disease following mediastinal radiotherapy for Hodgkin's disease



FARKAŠ ANTON

*DEPARTMENT OF INTERVENTIONAL CARDIOLOGY
UNIVERSITY HOSPITAL MARTIN, SLOVAKIA*



Late toxicity of radiotherapy



- **Thyroidal dysfunctions:**
 - Hypothyroidism
 - Hyperthyroidism
 - Benign and malign thyroidal nodes
 - 17% of patients after RT <26 Gy had thyroids abnormalities vs. 78% pts. >26 Gy

Late toxicity of radiotherapy

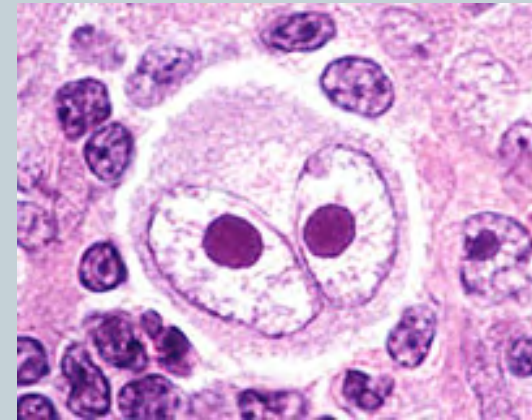


- **Cardiovascular diseases**
 - Pericardial diseases
 - Valvular diseases
 - **Coronary heart disease**
- **Pulmonary diseases**
 - Decreasing of ventilations parameters
- **Sterility/Infertility**
- **Increasing incidence of the secondary carcinomas**

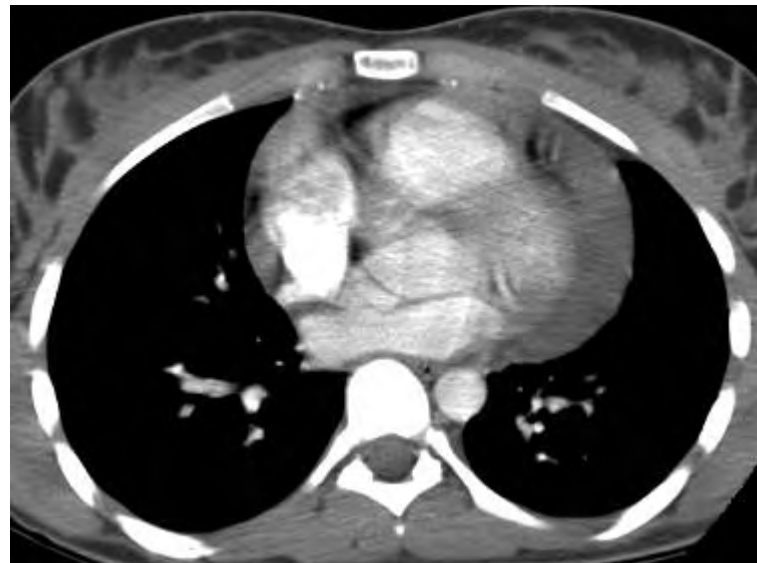
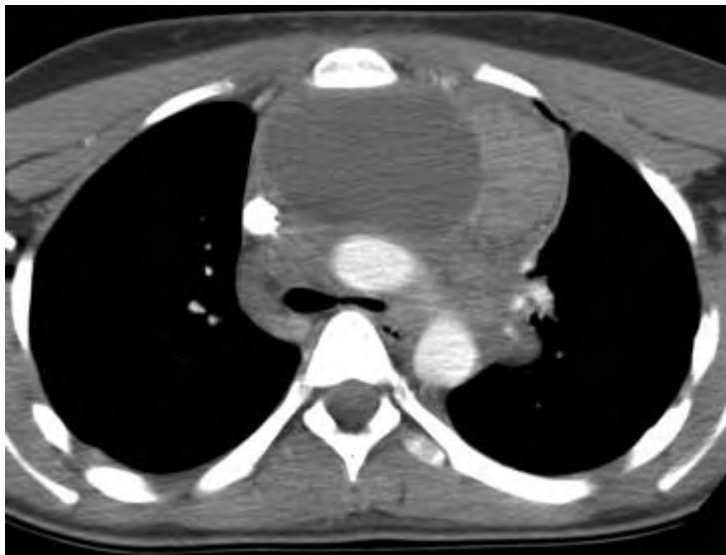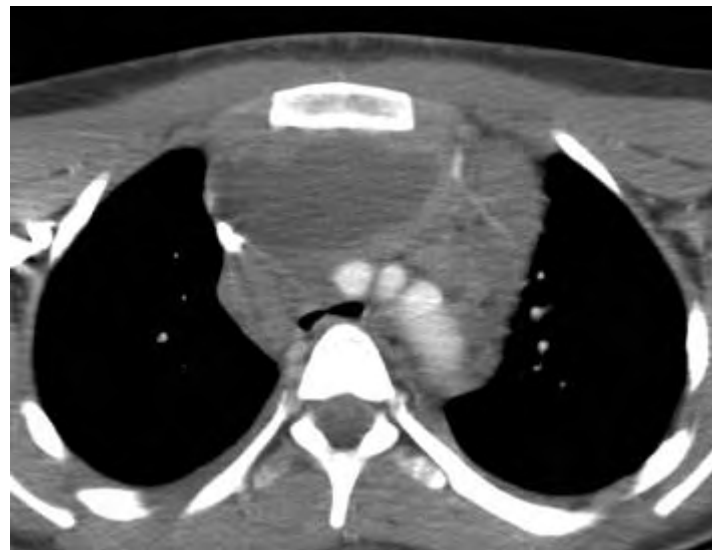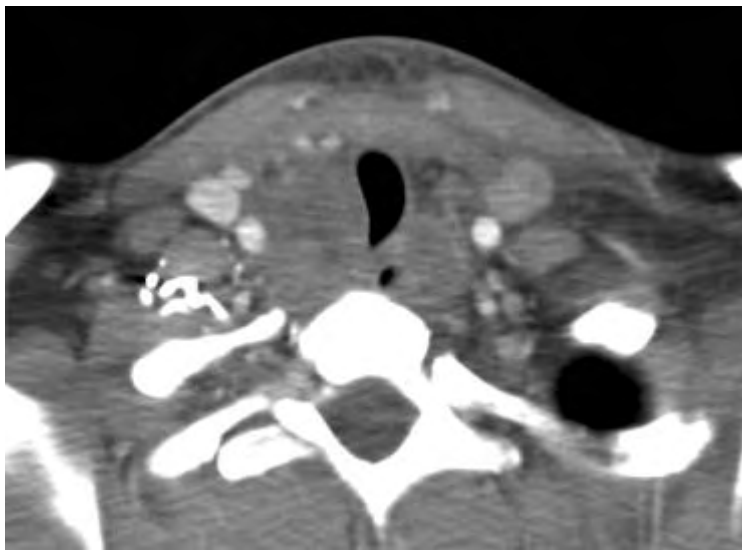
Patient`s history



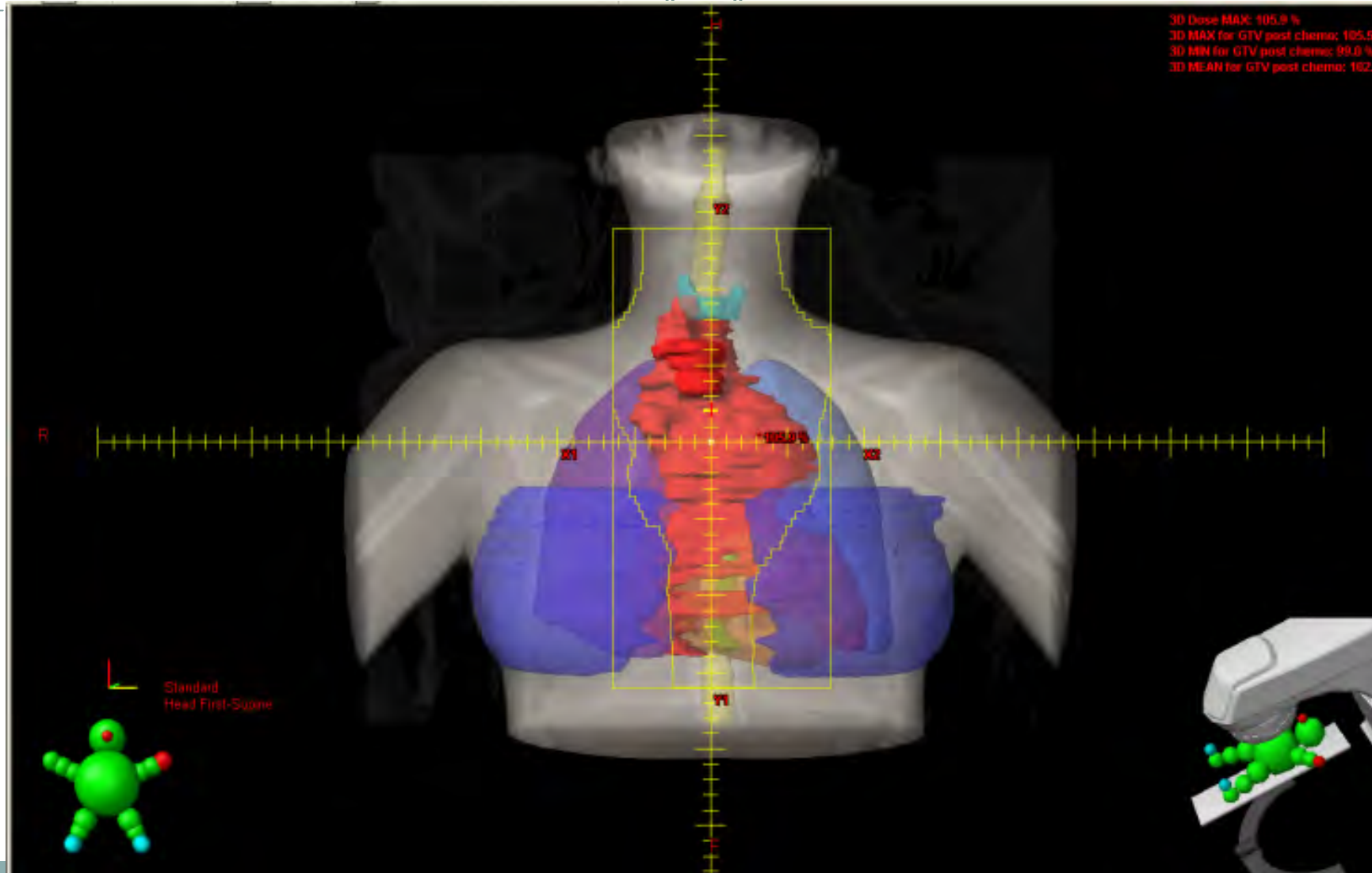
- 16-years old
- Left supraclavicular and right axillary lymphadenopathy
- Lymph node biopsy: stage IIA (NSHD) mixed cellularity Hodgkin's disease



Chest CT /year 1989/



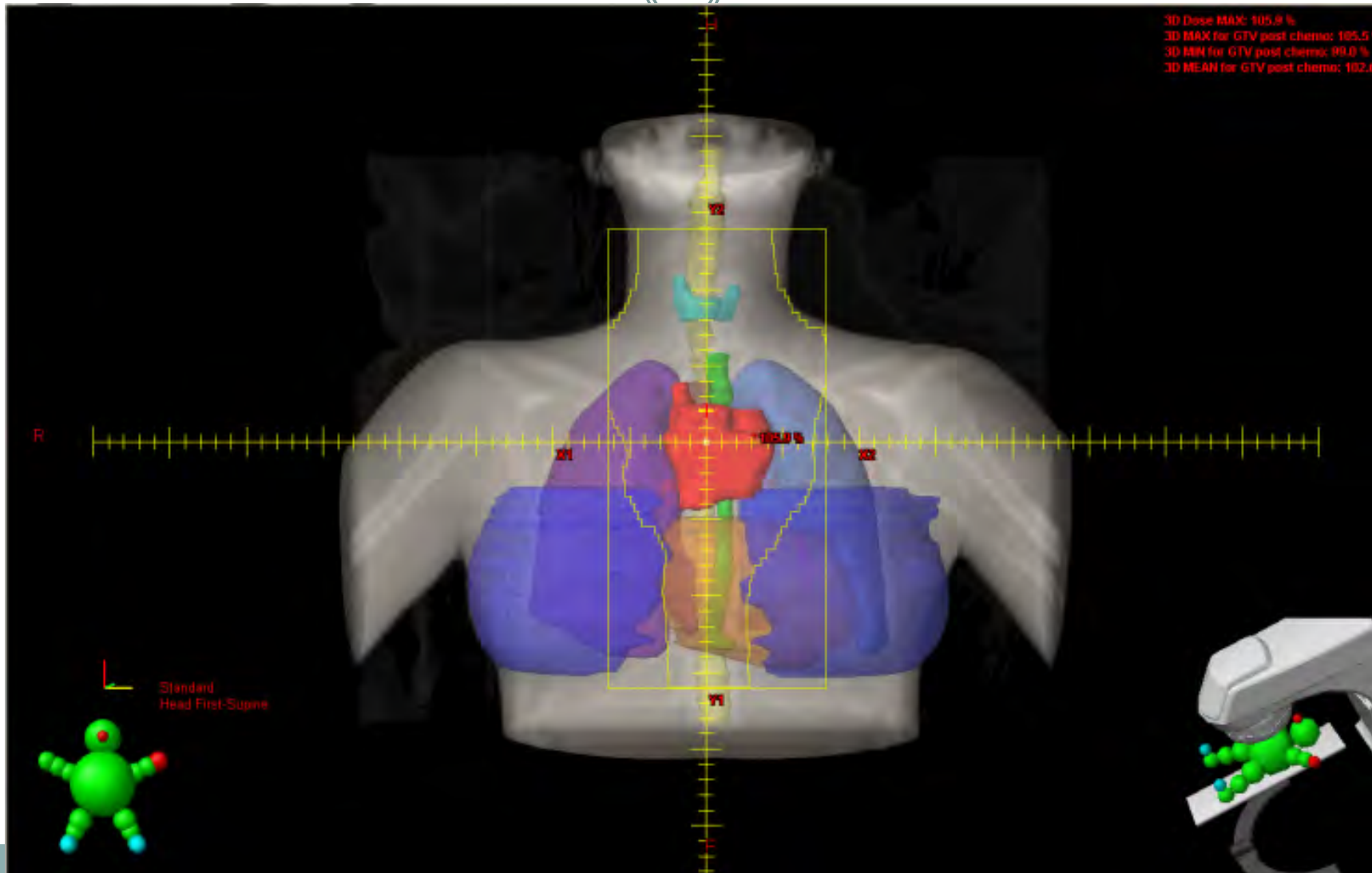
Mediastinal radiotherapy – before chemotherapy



Scheme for treatment in patients with early forms of the Hodgkin`s disease

Study Group/Trial	Sample Size	Treatment	Event-Free or Disease-Free Survival	Overall Survival	Follow-up (Years)
Stanford ⁴³	44 (CS/PSI-III)	3 MOPP/3 ABVD + 15-25.5 Gy IFRT	100	100	10
French Society of Pediatric Oncology ⁴⁶	65	4 ABVD + 20-40 Gy IFRT	90		4
	67	2 MOPP/2 ABVD + 20-40 Gy IFRT	87		4
St. Jude's Children's Research Hospital ⁴⁵	28 (CSII)	5 COP(P)/4 ABVD + 20 Gy IFRT	96	96	5
French Society of Pediatric Oncology MDH-90 ⁵¹	202	4 VBVP + 20 Gy IFRT (good responders)	91	97.5 (all)	5
		4 VBVP + 1-2 OPPA + 20-40 Gy IFRT (poor responders)	78		
Stanford/St. Jude/Dana Farber ⁵⁰	110	4 VAMP + 15-25.5 Gy IFRT	93	99	5
U.S. Children's Cancer Group ⁴⁹	294	4 COPP/ABV + 21 Gy IFRT	100 (IFRT)	100 (IFRT)	3
German Multicenter HD-90 ⁴⁷	267	2 OPPA/OEPA + 20-35 Gy IFRT	94	99.6	5
		2 OPPA/OEPA + 20-35 Gy IFRT	94		
German Multicenter HD-95 ^{48,52,93}	281	2 OPPA/OEPA + 20-35 Gy IFRT	94	NA	5
U.S. Pediatric Oncology Group ⁹⁶	46	4 DBVE + 25.5 Gy IFRT	91	98	6

Mediastinal radiotherapy – after chemotherapy

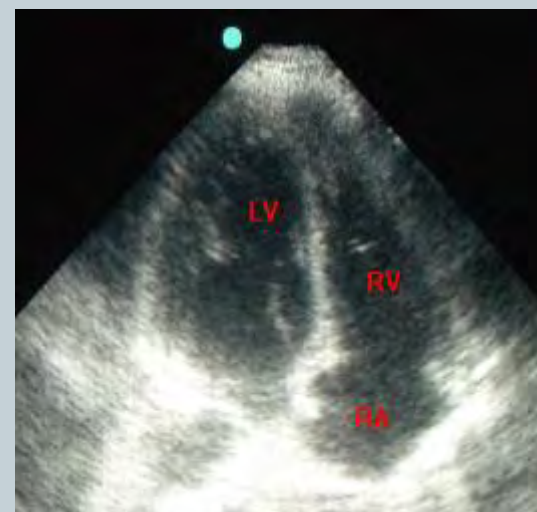
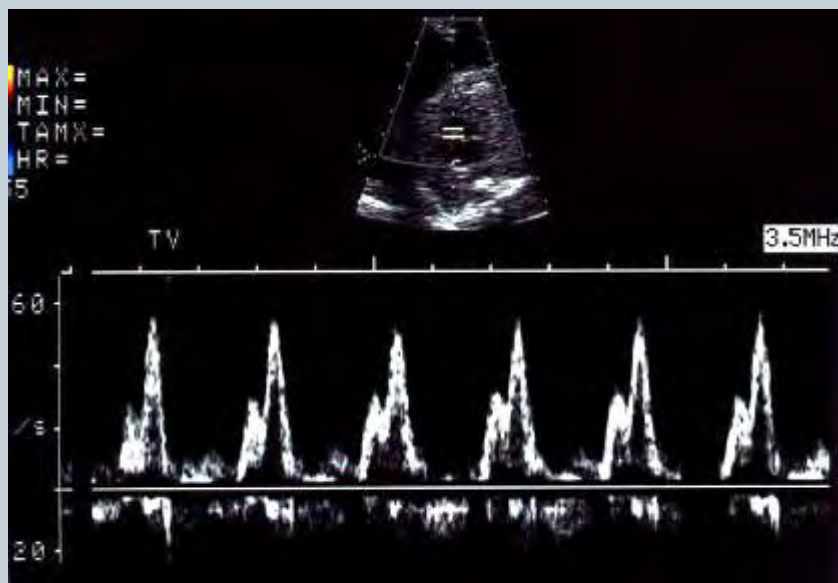


Year 2009



- 35-year old
- Planned heart catheterisation for chest pain and ECG changes during stress test
- Family history: non-significant
- Non-smoker, daily walking
- Atherogenic index 0,095
- HbA1C in normal ranges

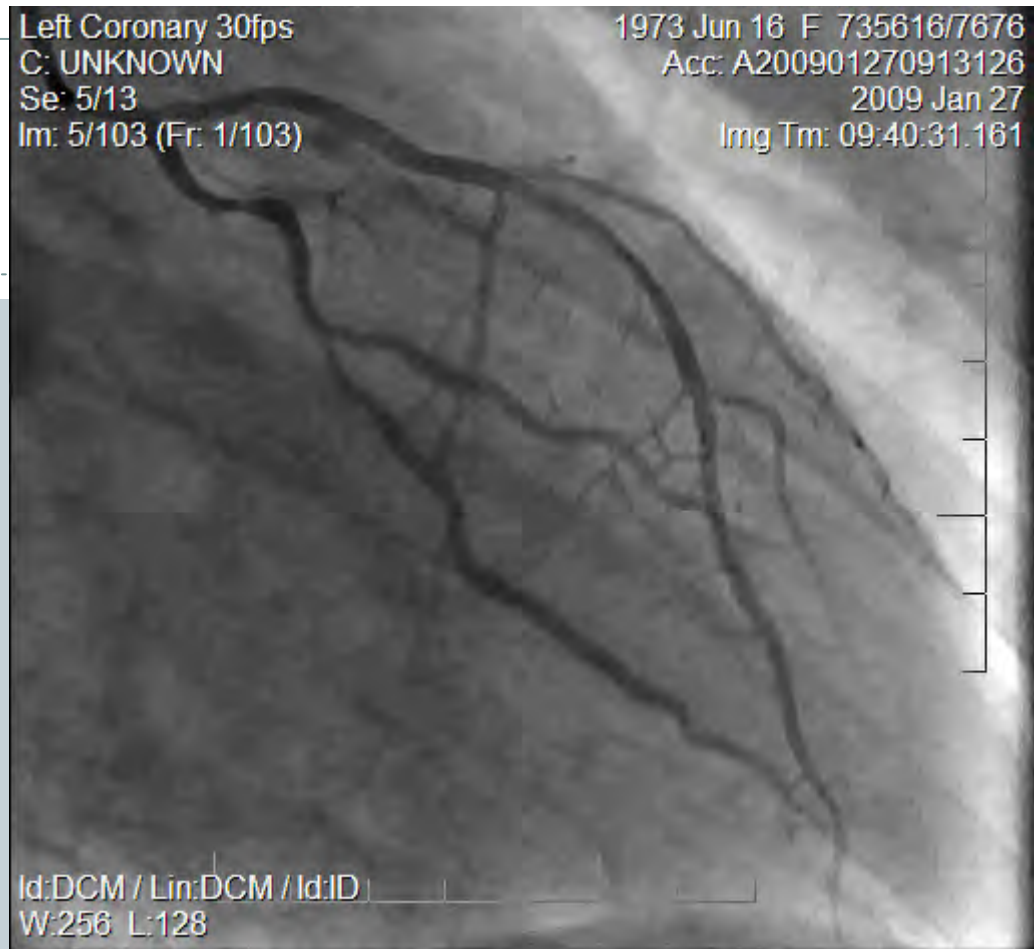
Echocardiography



Left Coronary 30fps
C: UNKNOWN
Se: 5/13
Im: 5/103 (Fr: 1/103)

1973 Jun 16 F 735616/7676
Acc: A200901270913126
2009 Jan 27
Img Tm: 09:40:31.161

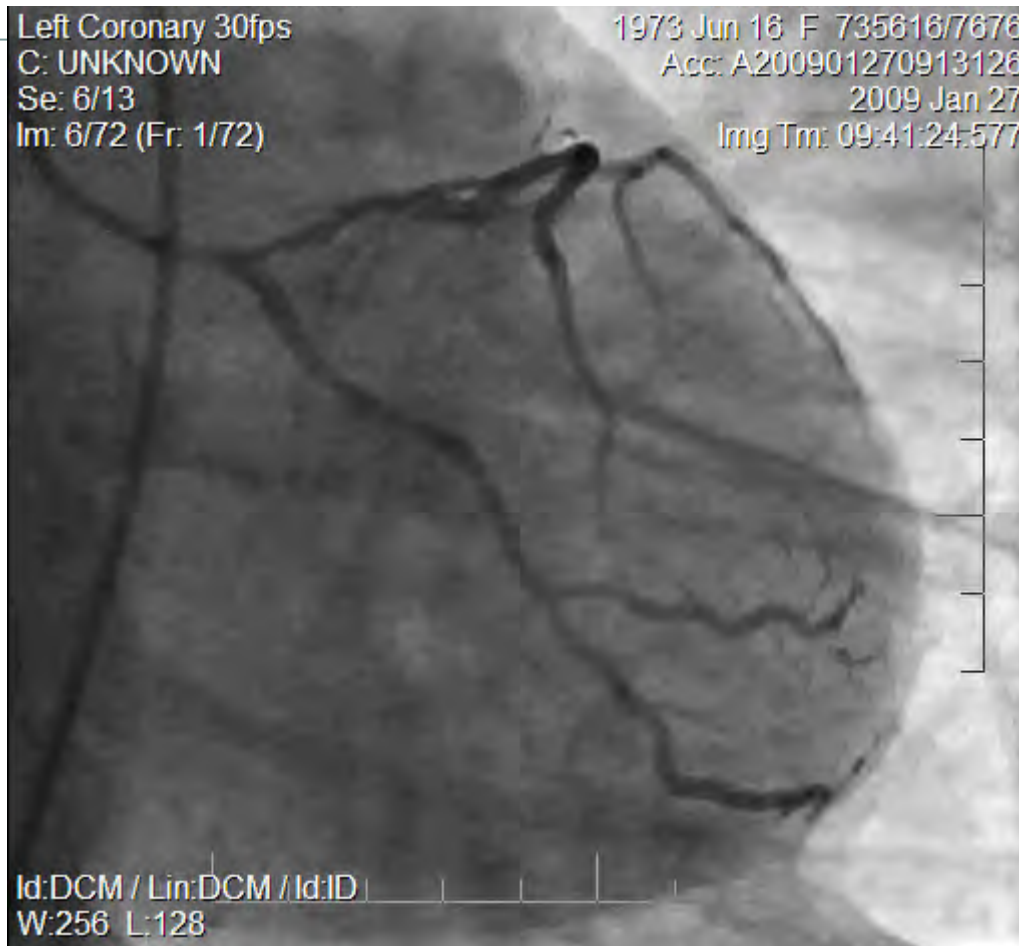
Id:DCM / Lin:DCM / Id:ID
W:256 L:128



Left Coronary 30fps
C: UNKNOWN
Se: 6/13
Im: 6/72 (Fr: 1/72)

1973 Jun 18 F 735616/7676
Acc: A200901270913126
2009 Jan 27
Img Tm: 09:41:24.577

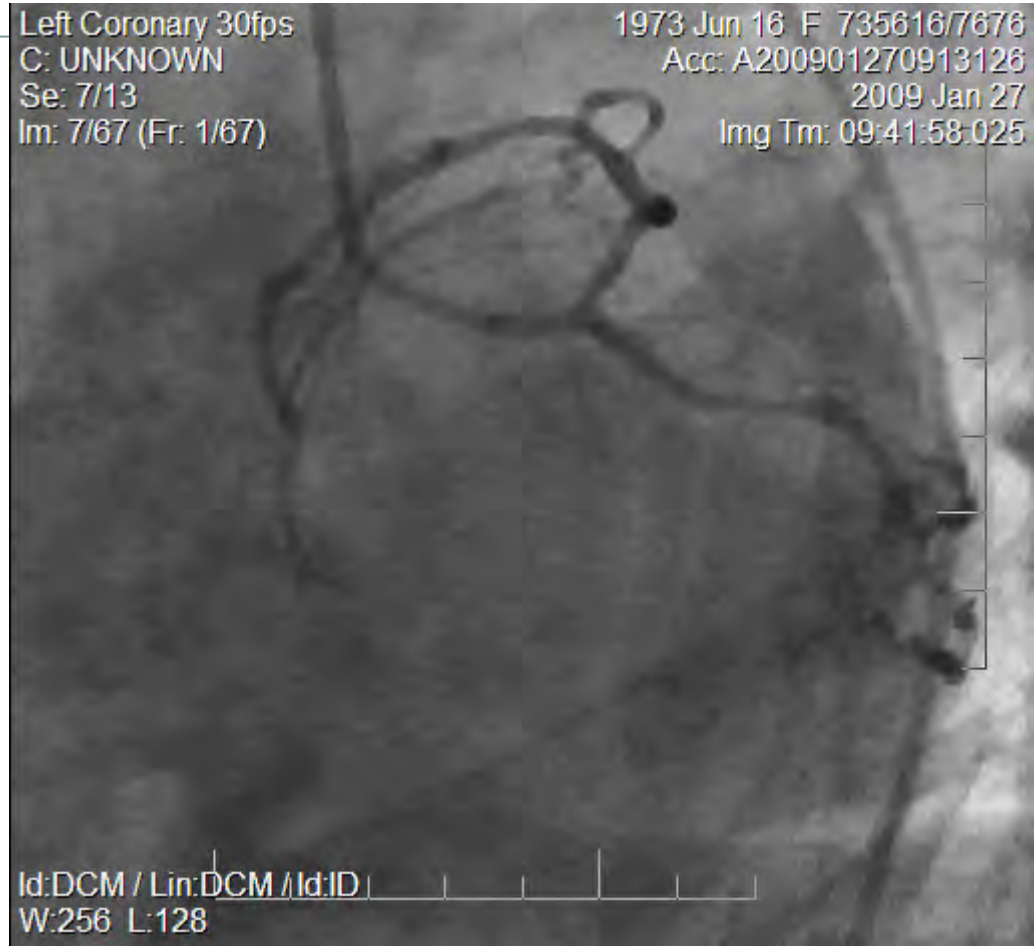Id:DCM / Lin:DCM / Id:ID
W:256 L:128



Left Coronary 30fps
C: UNKNOWN
Se: 7/13
Im: 7/67 (Fr: 1/67)

1973 Jun 16 F 735616/7676
Acc: A200901270913126
2009 Jan 27
Img Tm: 09:41:58.025

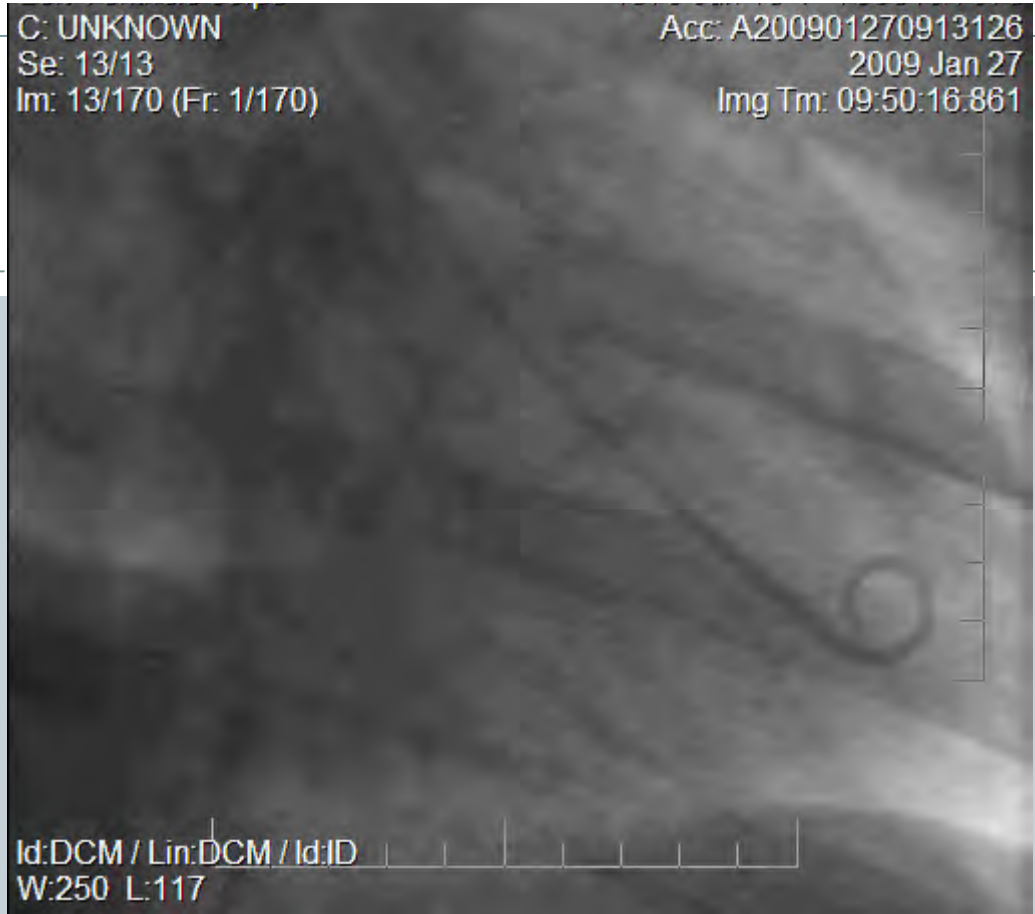Id:DCM / Lin:DCM / Id:ID |
W:256 L:128



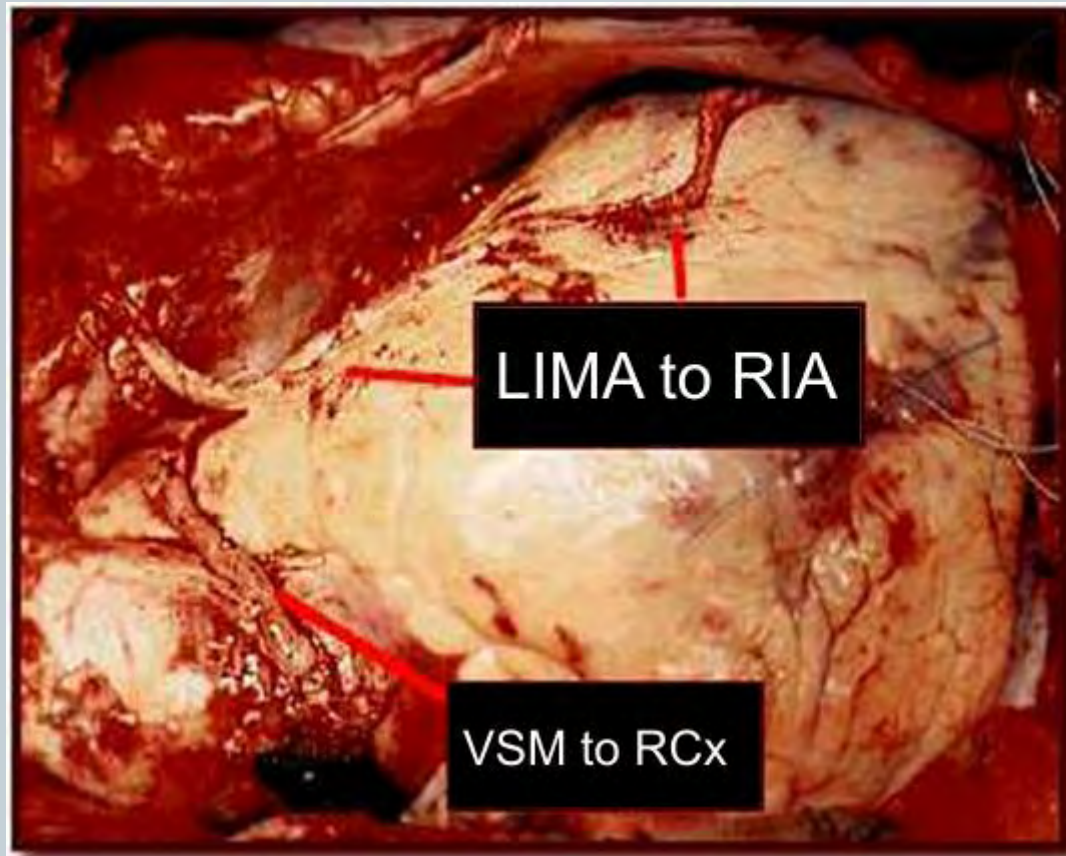C: UNKNOWN
Se: 13/13
Im: 13/170 (Fr: 1/170)

Acc: A200901270913126
2009 Jan 27
Img Tm: 09:50:16.861

Id:DCM / Lin:DCM / Id:ID
W:250 L:117



CABG



LIMA to RIA

VSM to RCx

Conclusions I.



- ❑ The mechanism of radiation induced coronary artery disease is particularly unclear.
- ❑ Cardiac complications of radiotherapy are dose related and may not become apparent for several years.
- ❑ Some studies with electron microscopy have shown damage to the cytoplasm of the capillary endothelial wall. This may lead to degeneration of the cell with thrombosis or capillary rupture (or both) and possibly with endothelial proliferation and a tendency for thrombosis.

Conclusions II.



With the improving survival of patients with mediastinal tumours relating from radiotherapy, recognition and appropriate management of potential cardiac complications are important; however, the optimal management of radiotherapy related coronary artery lesions remains to be established.