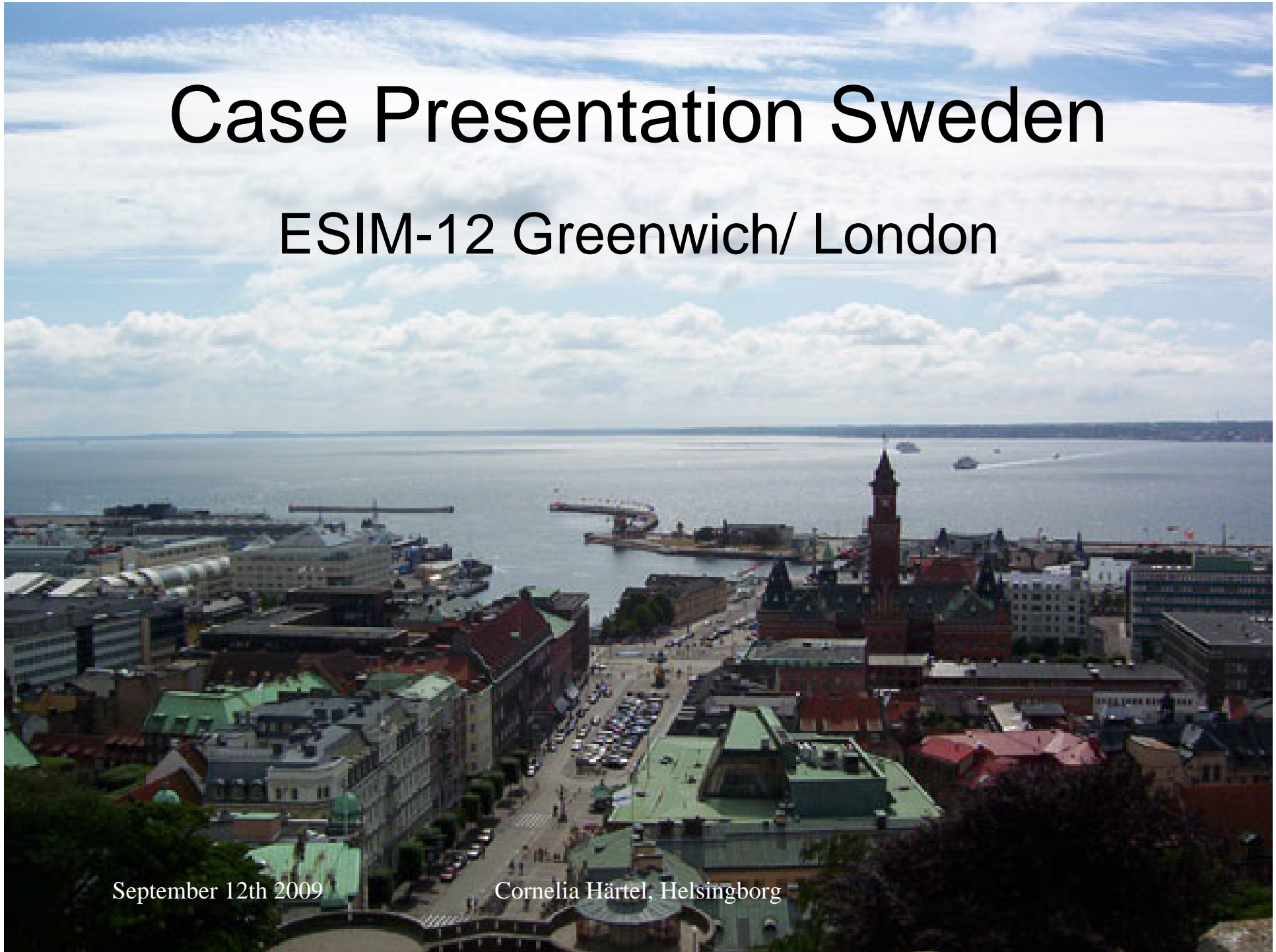

Case Presentation Sweden

ESIM-12 Greenwich/ London

September 12th 2009

Cornelia Härtel, Helsingborg



History of Present Illness

- 54-year old man presents to the ED with hx/o fever, generalised pain and weakness especially in prox limbs since 4/7.
- According to son more and more confused since last pm.
- PHx: NIDDM°II.
- Current Medications: T Glucophage 500mg OD.
- Allergies: NKTD.
- Lifestyle: Smoker (30 py), nil alcohol, nil drugs.
- Social: Divorced, truckdriver, lives with one of his sons.

Physical Exam

- VS - HR 130/min, BP 150/90, RR 20/min, Sat 92% on 2l/min O2, Temp 39°.
- GEN - Confused. Looks pale and tired.
- CVS - RR. HS I + II,. No murmur. JVP not elevated.
- PULM – Normal breathsounds. No wheezes or crackles.
- ABD - Normal BS. Soft, NT, ND. No organomegaly.
- NEURO - **GCS 13/15 (E3, M5, V5)**. CN II-XII normal. No meningeal irritation. No lateralising signs. Plantar ↓bilat.
- SKIN - Pale. Warm and dry. No rashes.

Investigations

- ECG: Sinustakycardia. Nil ischemic.
- CXR: Nad.
- Urindip: Nad.
- MSU: WBC 0, RBC 0.
- Bloods and ABG ...

	Normal values	Pat result
CRP	< 5.0 mg/L	354
Hb	134 - 170 10 ⁹ /L	153
WBC	3.5 - 8.8 10 ⁹ /L	12.3
Plt	145 - 348 10 ⁹ /L	77
Glucose	mmol/L	20.4
pH	7.35-7.45	7.49
PaCO ₂	4.6-6.0 kPa	3.9
HCO ₃ ⁻	21 - 27 mmol/l	24
Base excess	± 3 mmol/L	± 0
PaO ₂	8.0 - 13.0 kPa	13.8
Lactate	0.5 - 1.6 mmol/L	3.2

- U&E, LFT, Coags normal. Diff not done.
- Blood-, urincultures.

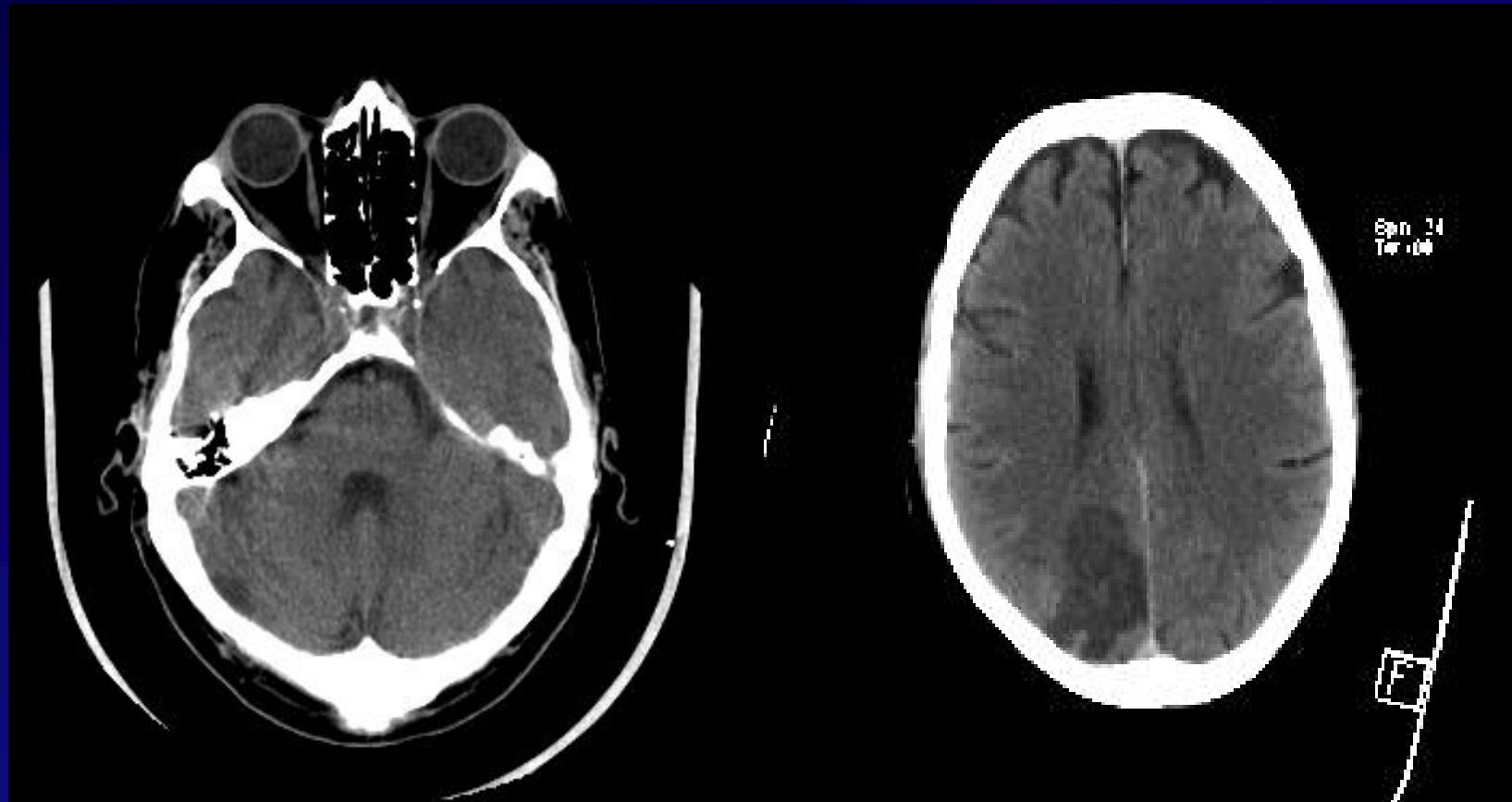
Differential Diagnosis

- Treatment started with iv Cefotaxim 1g TDS and Gentamycin 300mg OD for query septicemia without known focus.

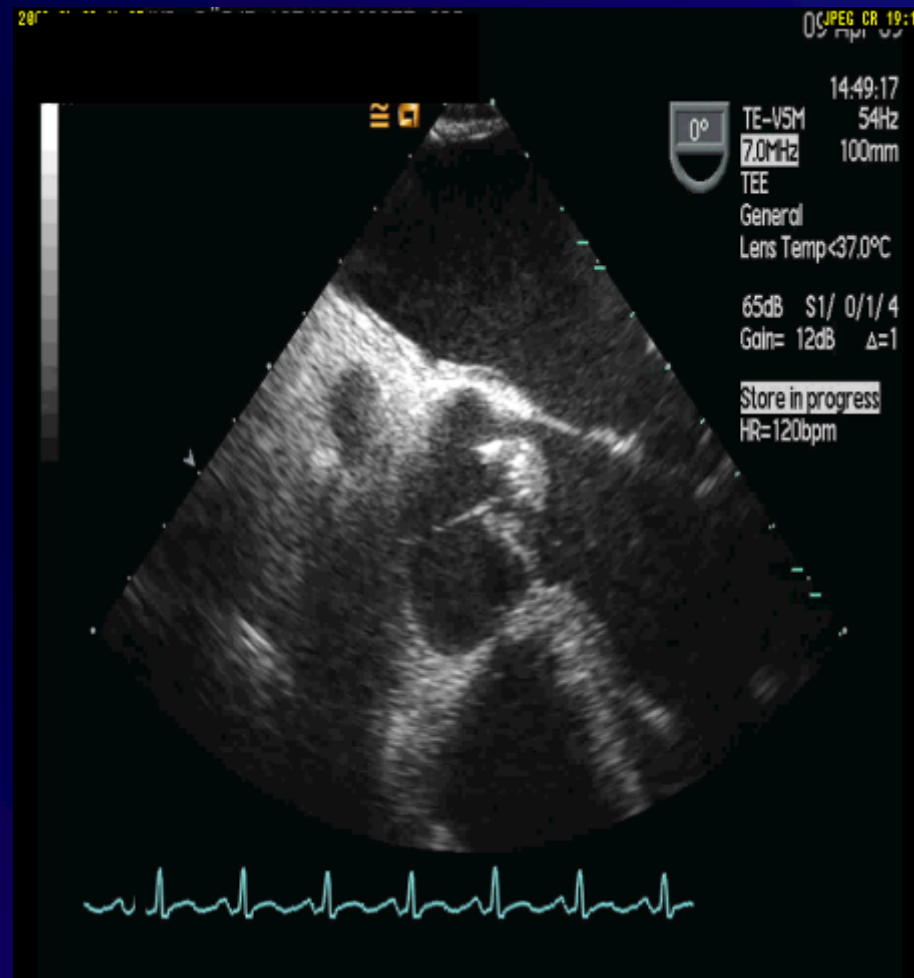
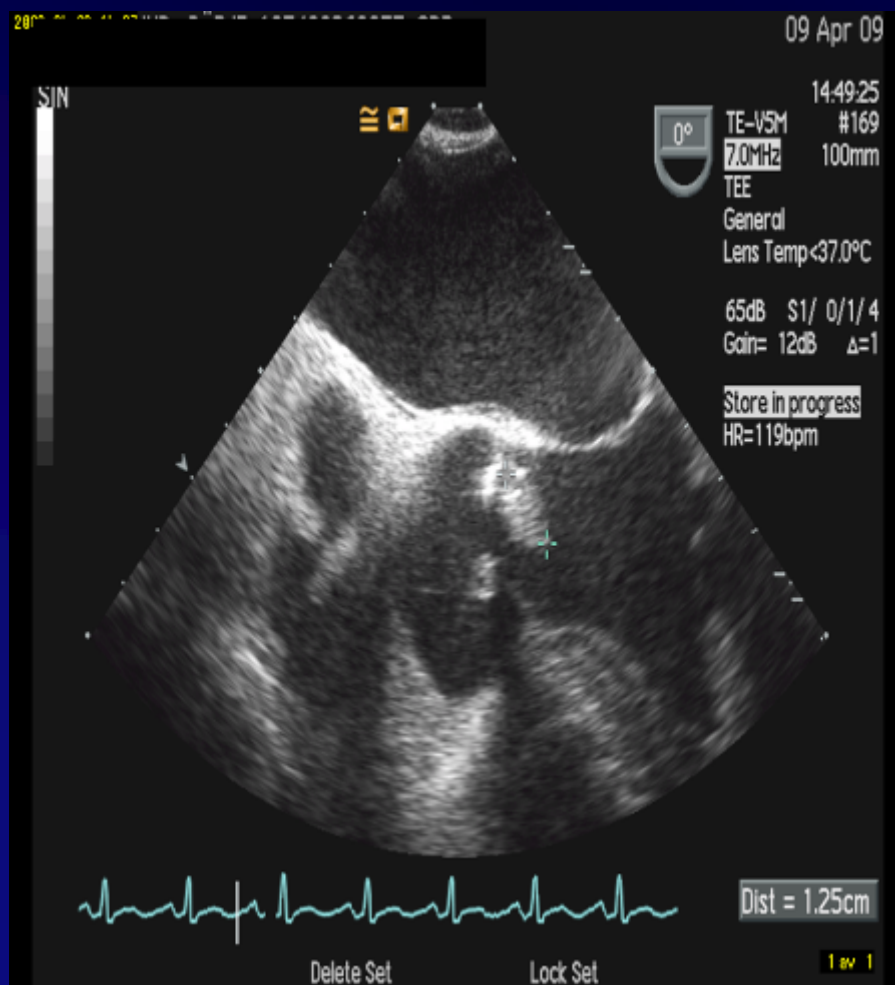
d2

- Bloodcultures gramstain + cocci (Staph. aureus).
- Pat getting more confused.
- Left-sided upper limb paresis (3/5) and left lower quadrantanopsia.
- Nil other changes in physical exam.

cCT d2



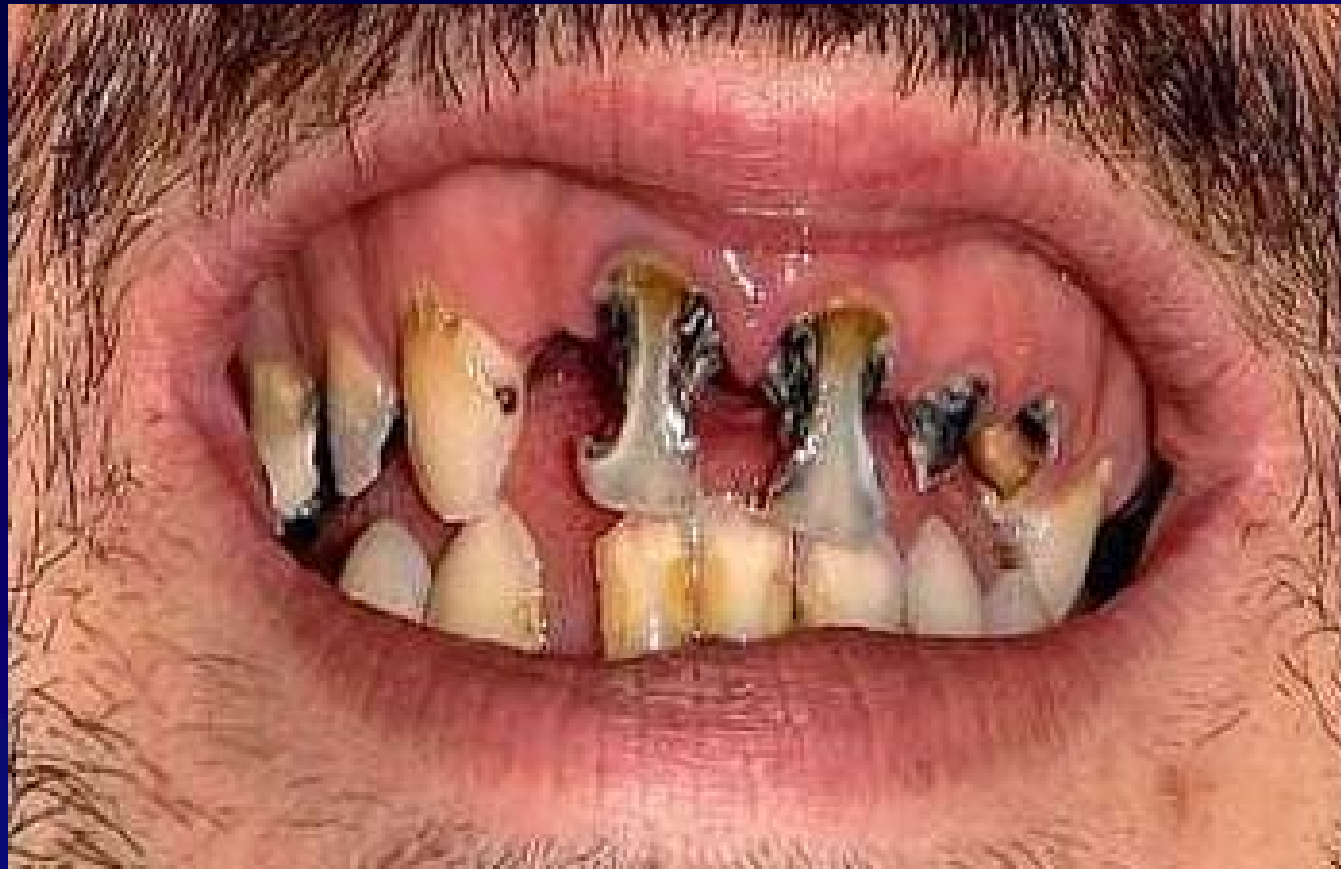TEE d2



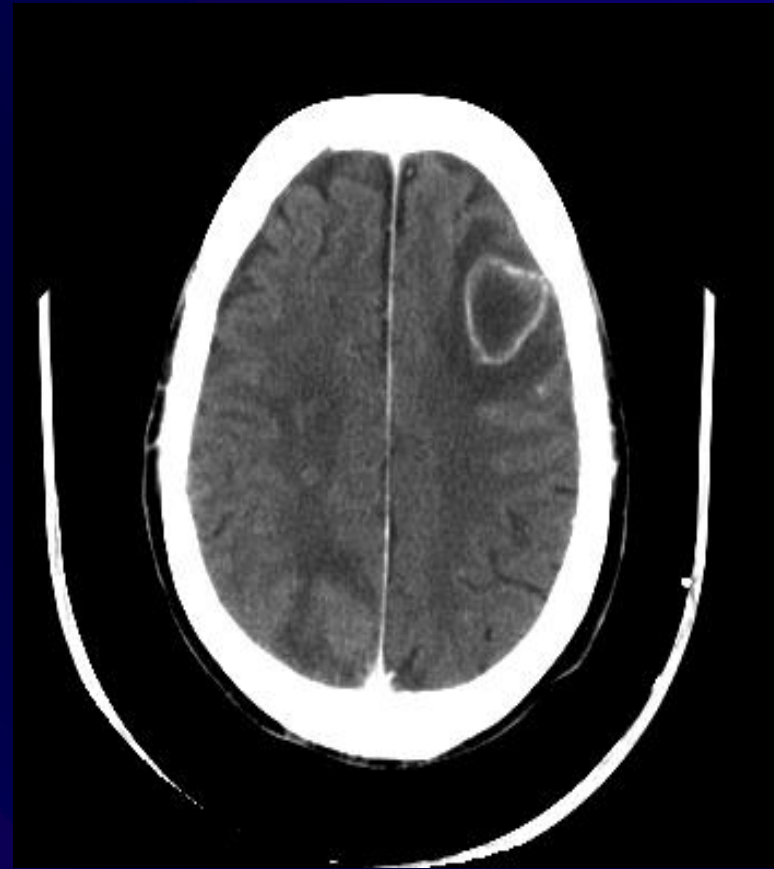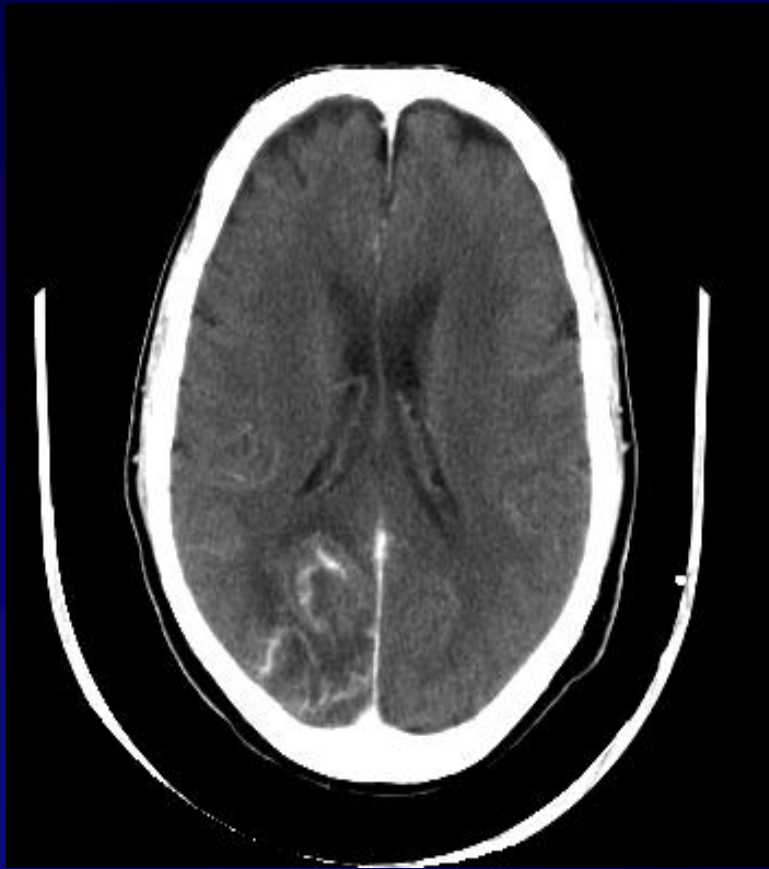Follow-up

- Pat received a biological aortic valve replacement.
- LMWH sc 6/52.
- Antibiotics 6/52 (iv Flucloxacillin 2g QDS, iv Gentamycin 300mg OD).
- Ergo- and Physiotherapy.
- Control-cCT 21d after cardiothoracic surgery.
- Looking for infectionfocus.

Infectionfocus



cCT d24



Follow-up

- Abscess drainage via neurosurgery.
- Antibiotics 6/52 (iv Cefotaxim 3g TDS, iv Gentamycin 300mg OD and po Rifampicin 600mg OD - due to intracerebral abscesses).
- Continued Ergo- and Physiotherapy.
- Dental sanitation.
- Pat D/C d66 with full recovery.

Summary Infective Endocarditis (IE)

- History
- Complete physical examination
- Typical causes:
 - * Staphylococcus aureus
 - * Streptococci viridans and bovis
 - * Enterococci
- Investigations (bloods, ECG, CXR, TEE/TTE)
- Rec. treatment (in unknown organism):
Vancomycin (30 mg/kg per 24 h IV in 2 divided doses)**

**Baddour, LM, Wilson, WR, Bayer, AS, et al. Infective endocarditis: diagnosis, antimicrobial therapy, and management of complications. Circulation 2005; 111:3167.





Thank you



**EFIM
2010**

9th CONGRESS
of the European Federation
of Internal Medicine

21–24 September 2010
Stockholm, Sweden



www.efim2010.org

The poster features a large red vertical bar on the left side. At the bottom of this bar are two circular logos: a green one with a white maple leaf and a blue one with a white globe. The main image is a photograph of a Swedish flag flying from a ship's mast, with a building and water in the background.

Tack

See you all in Stockholm next year...