

Case Presentation

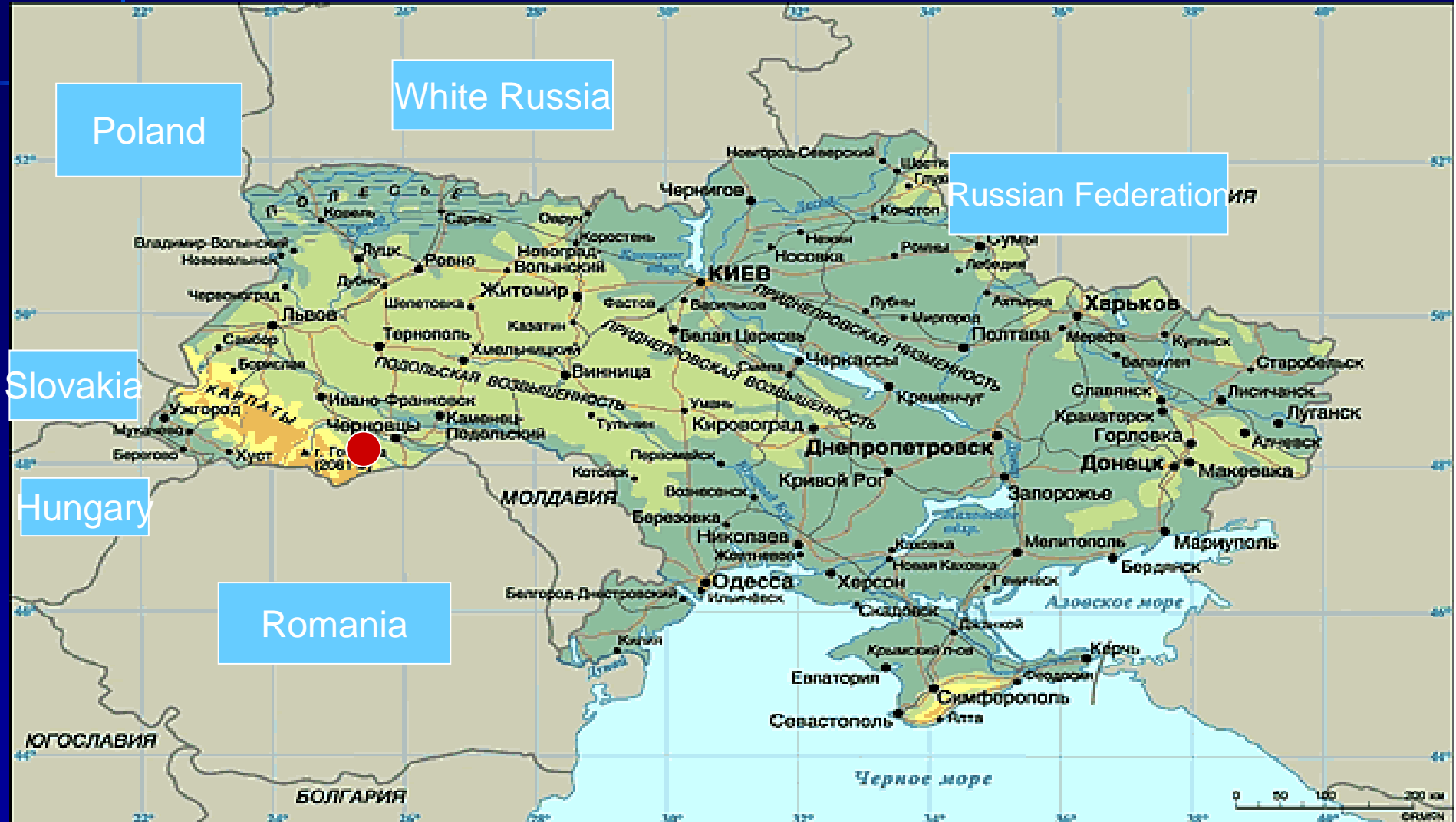National Medical University

Ukraine, Kiev

Nonna Netiazhenko

Galyna Mishanych

Ukraine



Case Presentation

- 54-year-old male
- Acute epigastric pain >40 min, vomiting and diarrhea one-time at **20th of June 2009** during the long voyage in South Africa
- Admission to a gastroenterology unit with discomfort in epigastria, sickness, weakness and abdominal swelling at **28st of June 2009, 07:00 am**

Gastroenterology unit

Painless palpation in epigastria

Laboratory results –no abnormality

Ultrasound examination- no abnormality

Gastroduodenoscopy- no abnormality

What next?...

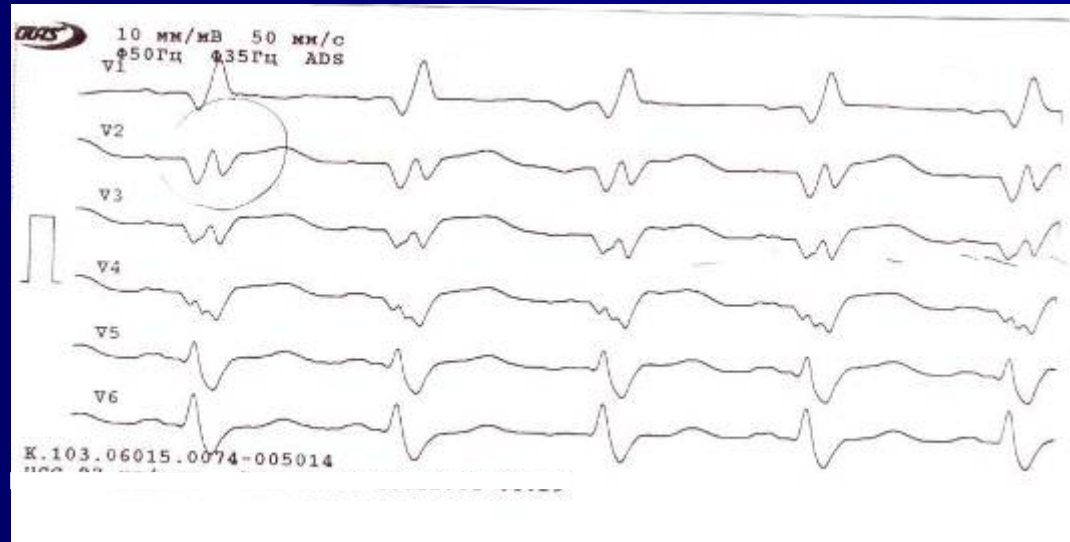
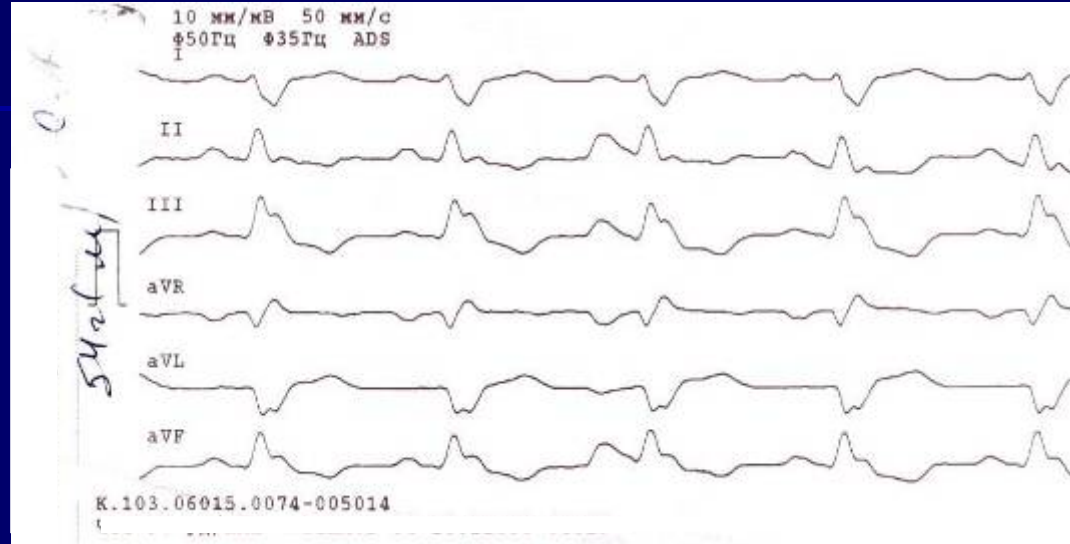
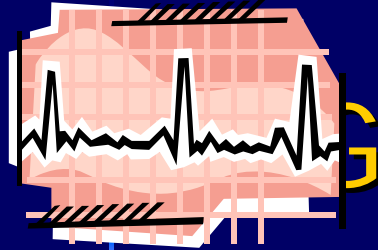
Case presentation

29nd of June 2009 (9 day after first symptoms)

- ↓ **Blood Pressure 80-90/50-60 mm Hg**
- ↓ **Sa O₂ 86-80-78%**
- ↓ **Diuresis 500 ml/day**
- **pHa – 7.1 pO₂ – 37**

ICU

- Intubation
- ECG
- Troponin
- Echo-CG



Echocardiogram

Aorta – 28 mm

LA - 36×52 mm

RV – 23 mm

Vena cava inferior- 17 mm

LV: EDV – 144 mm
39%

ESV - 86 mm

EF –

IVS - 1,0 cm, paradoxical movement

Posterior wall - 1,0 cm, akinesia

Lateral – middle zone hypokinesia

Anterior – apex segment hypokinesia

Apex – hypokinesia

Troponin T 2,3 ng/ml (0,05 ng/ml)

Acute Q-MI

- **Aspirin 325 mg/day**
- **Enoxaparin 80 mg bid**
- **Atorvastatin 40 mg 1/day**
- **Carvedilol 6,25 mg bid**
- **Diuretics (torasemid) 4 ml i/v**
- **Clopidogrel 75 mg 1/day**

Case Presentation

- **aortic balloon counterpulsation 1:1**
- **Symdax 12,5 mg i/v 24-hour, 0,1 mkg/kg/min**
 - **moxifloxacin 400 mg i/v**
 - **PCI relatives refused**

3rd day

- **Stop ALV**
- **PCI :**
 - Acute thrombosis in front interventricular artery → **BMS**
 - Circumflex artery 70% stenosis
 - Chronic occlusion in right coronary artery
 - CABG was recommended**

1st key point

**Don't forget about
atypical MI**

2nd key point

**Don't forget about
Greenwich !!!**

Don't forget about Ukraine !!!

