

ESIM-2009, Greenwich. Clinico-pathological conference-3



Ramon Pujol. Internal Medicine.

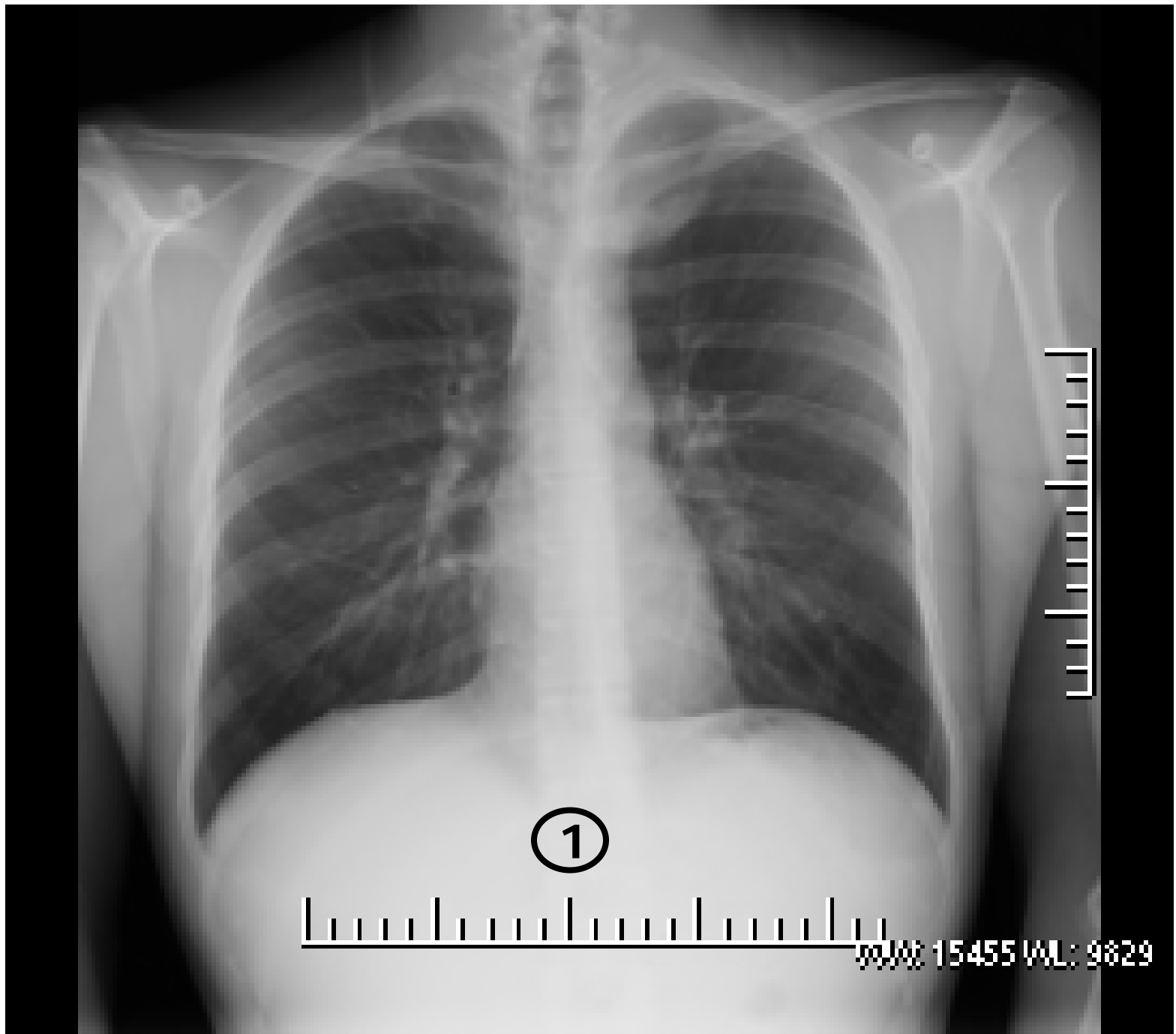


Tasks

- X-ray film interpretation
 - Differential diagnosis
 - Diagnostic procedure ?
 - Final diagnosis
-

Summary

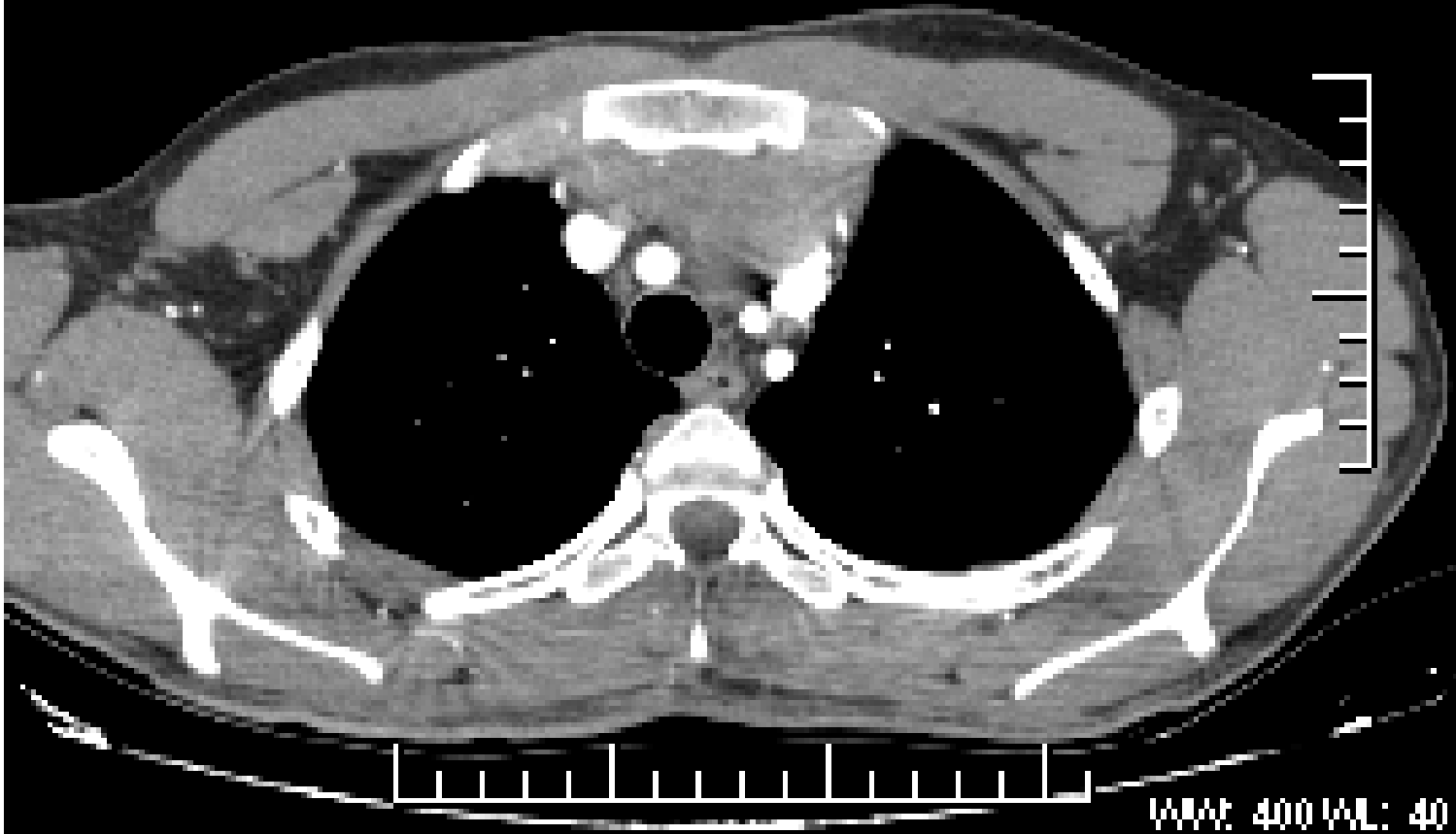
- Young male
 - Smoker; toothache
 - **NECK INFLAMMATORY LUMP**
 - No systemic complaints
 - Normal lab tests
 - X-ray film (.....)
 - 1 FNAP, 2 biopsies: inflammatory changes
 - PPD +
 - Serological tests performed: negative
 - No effective antimicrobial therapy
-



①

0000 15455 WL: 9829

②



Sagittal
Ex 21809
Se: 2
L: 41

2 69

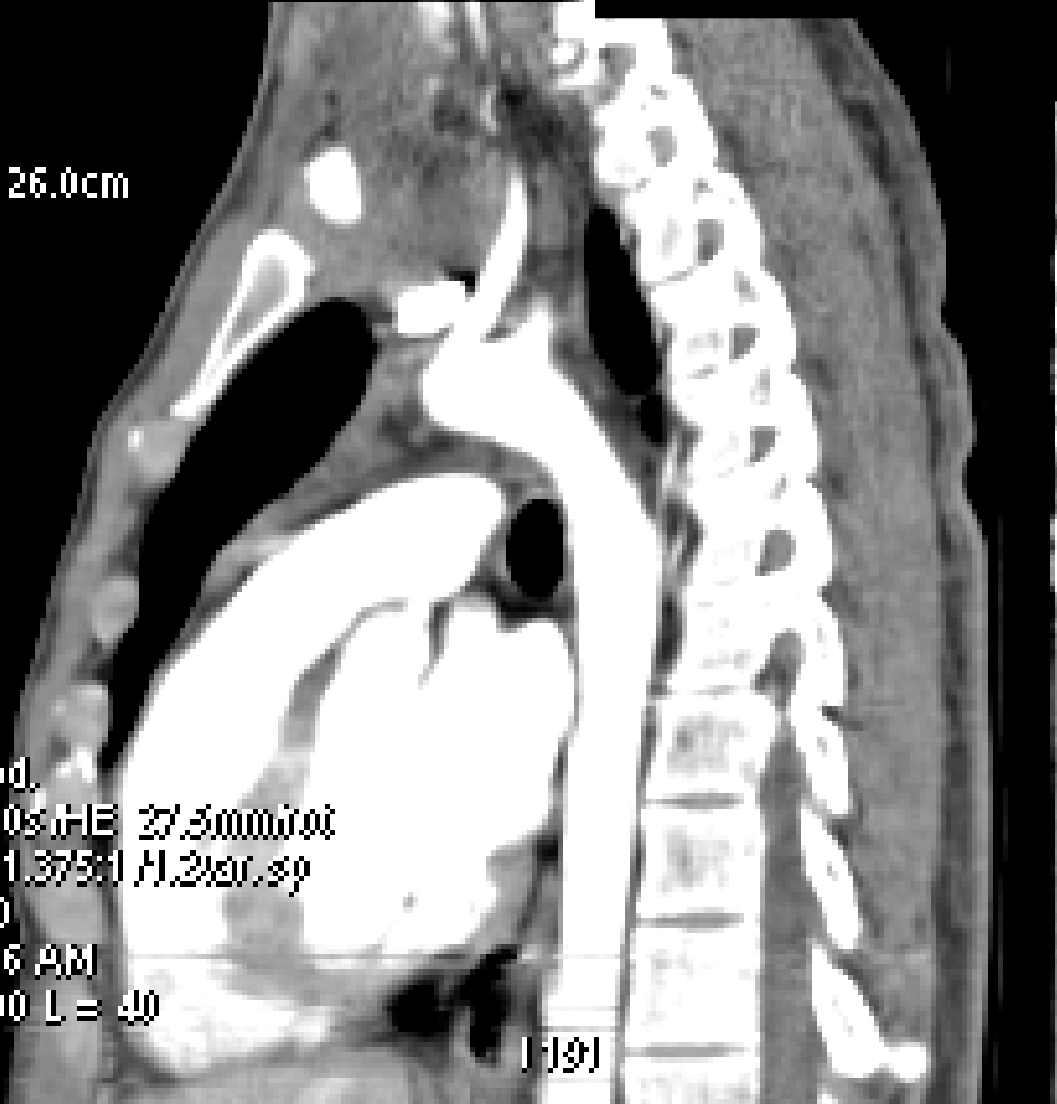
DFOV 26.0cm
STND

A
1
2
3

P
1
2
3

0.71
kV 120
mA Mod.
Rot 0.60s HE 27.5000000
1.2mm 1.375:1 H.2/cr.sp
Tilt 0.0
10:05:06 AM
W = 400 L = 400

1191



Asal2
Ex: 12530
Set: 2
I: 81.3
Im: 77

A 150

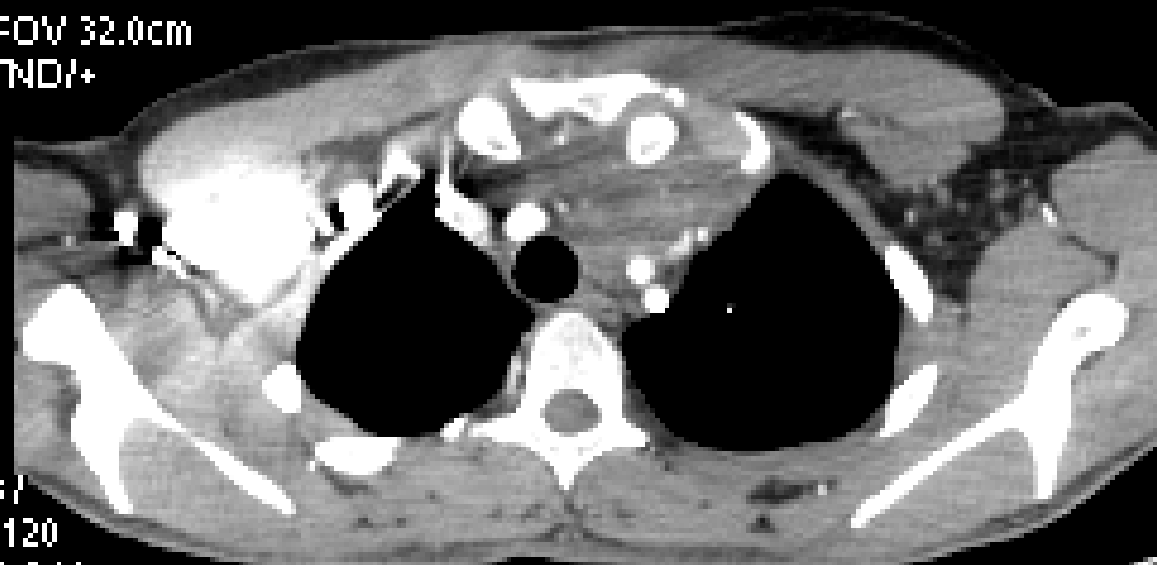
Hospital Universitari Bellvitge

3

DFOV 32.0cm
STND/+

R
1
7
5

L
1
8
8



0.87
kv 120
mA 244
Rot 0.6037 HE + 39.4mm Rot
1.2mm 0.984:170.8 sp
Tilt 0.0
09:36:04 AM
W = 350 L = 40

P 150

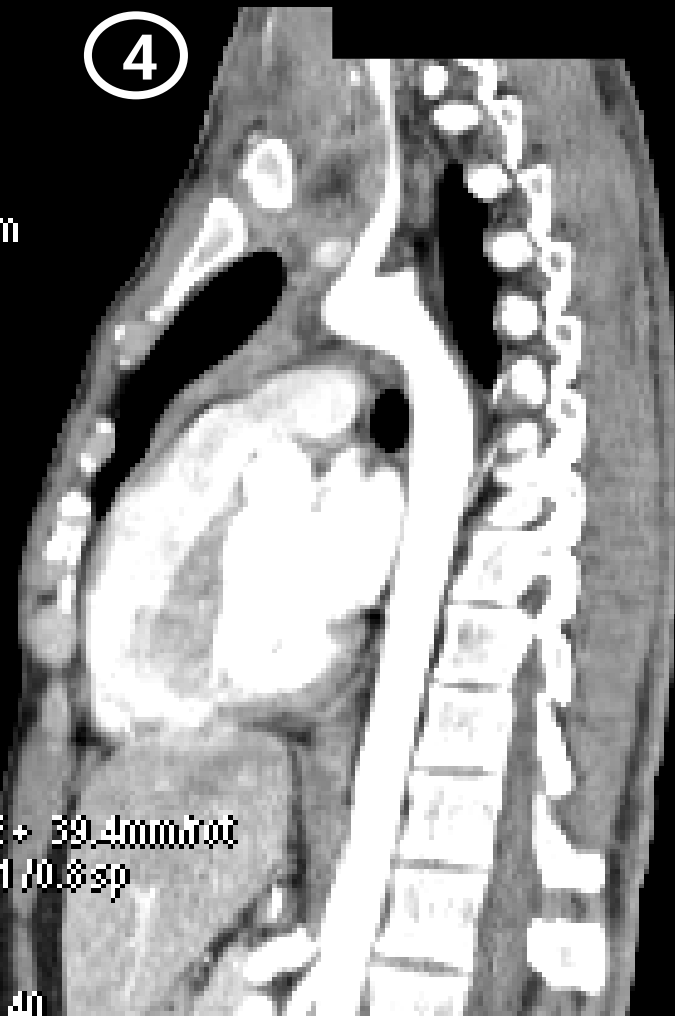
Sagittal
Ex 12530
Ser: 2
L: 19.0

4

DFOV 36.0cm
STND7+

A
2
0
4

0.77
kv 120
mA Mod.
Rot 0.60s HE + 39.4mm/rot
1.2mm 0.984:1/0.3sp
Tilt 0.0
09:36:04 AM
W = 363 L = 40



P
2
0
4

Neck lymphadenopathy

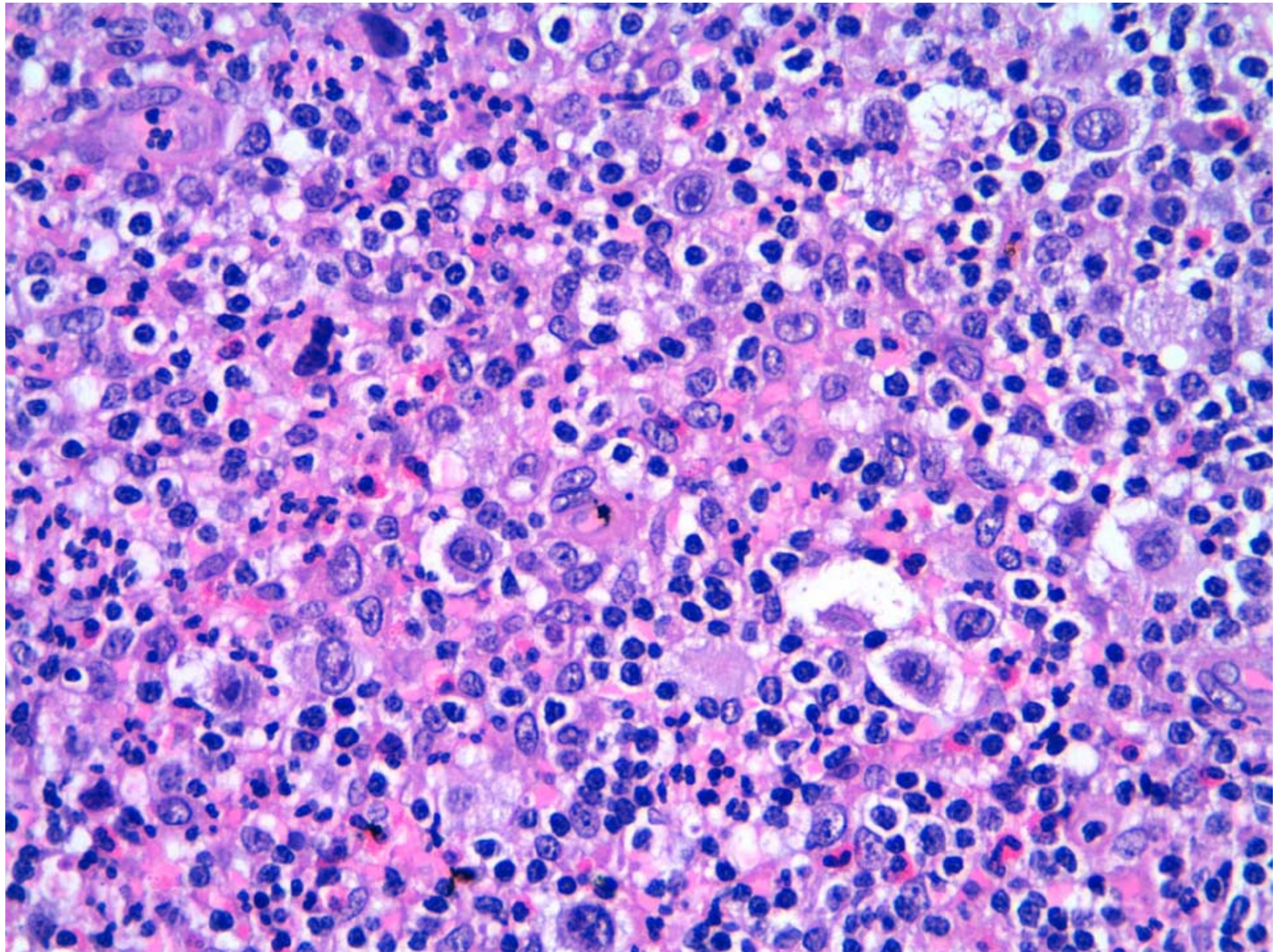
- Infection
 - Bacterial (pyogenic, cat-scratch, syphilis, tularemia)
 - Mycobacterial (tuberculosis, non-tbc. mcb.)
 - Fungal (histoplasmosis, coccidioidomycosis)
 - Chlamydial (lymphogranuloma venereum)
 - Parasitic (toxoplasmosis, trypanosomiasis, filariasis)
 - Viral (EB virus, cytomegalovirus, rubella, HIV, hepatitis)

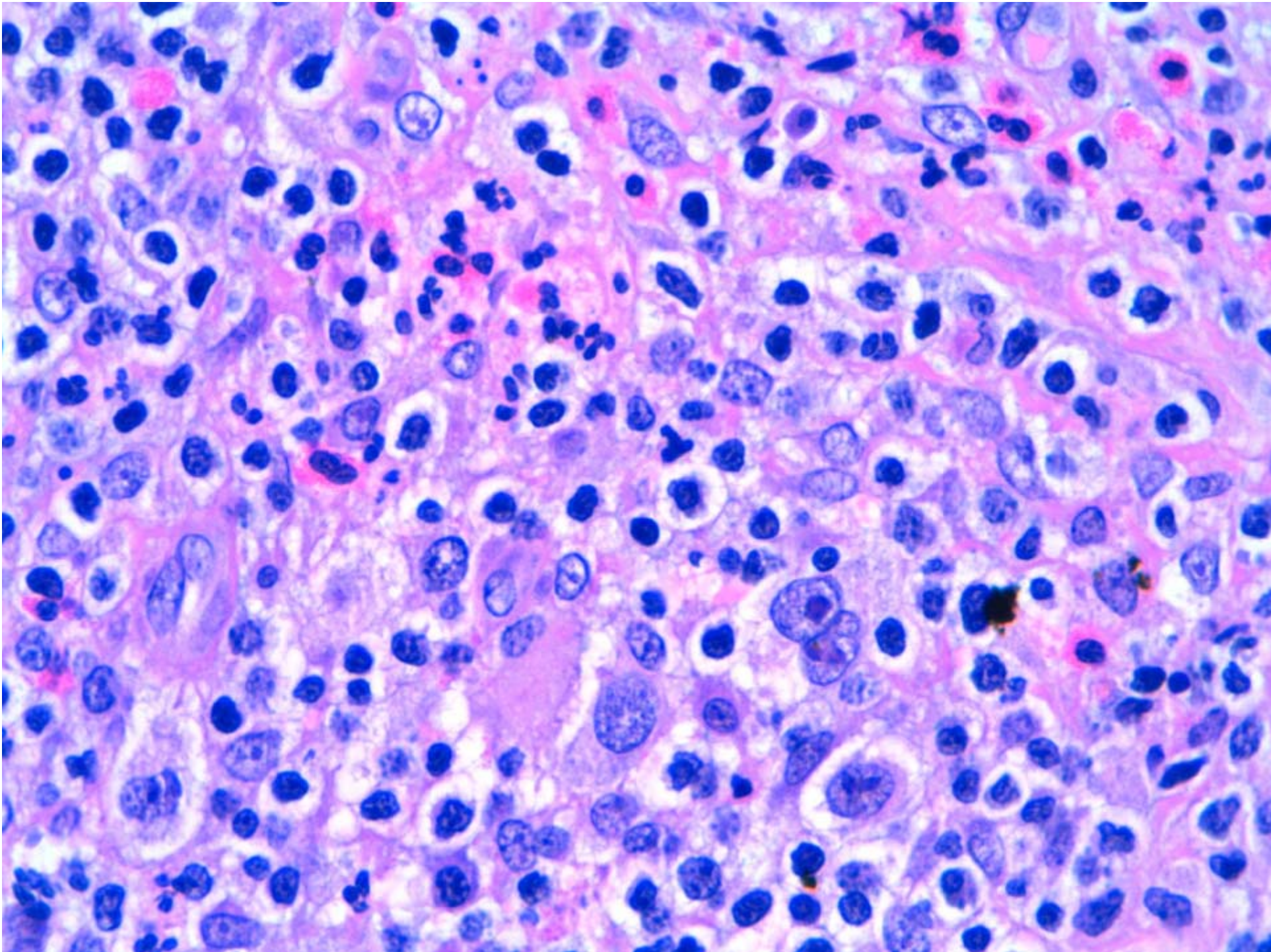
Neck lymphadenopathy

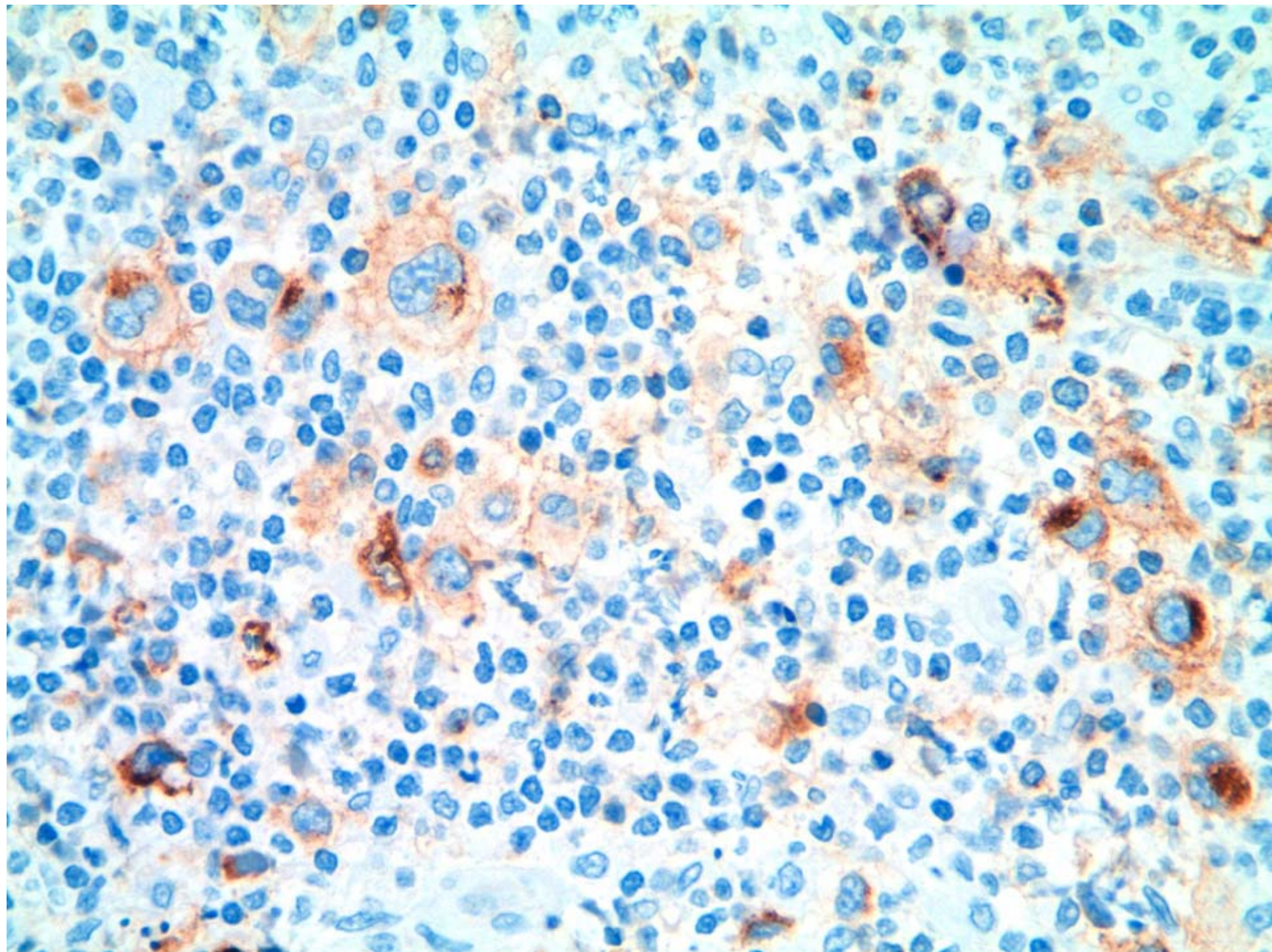
- Benign
 - RA, SLE, serum sickness, Kawasaki, drugs..
- Malignant
 - Leukemia, Hodgkin's and non-H lymphoma, Waldenström, histiocytosis, MM with amyloidosis
 - Head & neck cancer, breast, lung, GI carcinomas, Kaposi, germ cell tumors
- Storage disease (Gaucher, Niemann-Pick)
- Endocrinopathies (hyperthyroidism, adrenal insufficiency, thyroiditis)
- Miscellaneous
 - Sarcoidosis, dermatopathic lymphadenitis

Diagnostic procedure

New surgical biopsy of the lump







Hodgkin's lymphoma. Clinical presentation

- Painless mass (70%)
 - Neck (+++), axillary (+) or inguinal (+) nodes
- Mediastinal mass
- Systemic symptoms
 - Fever
 - Night sweats
 - Pruritus

- Nonspecific symptoms and paraneoplastic
 - Hepatosplenomegaly, ascites
 - Cholestatic liver disease
 - Skin lesions
 - Neurologic
 - Nephrotic syndrome

Mauch PM. 2009/www.uptodate.com

Hodgkin's lymphoma mimicking a suppurative disorder

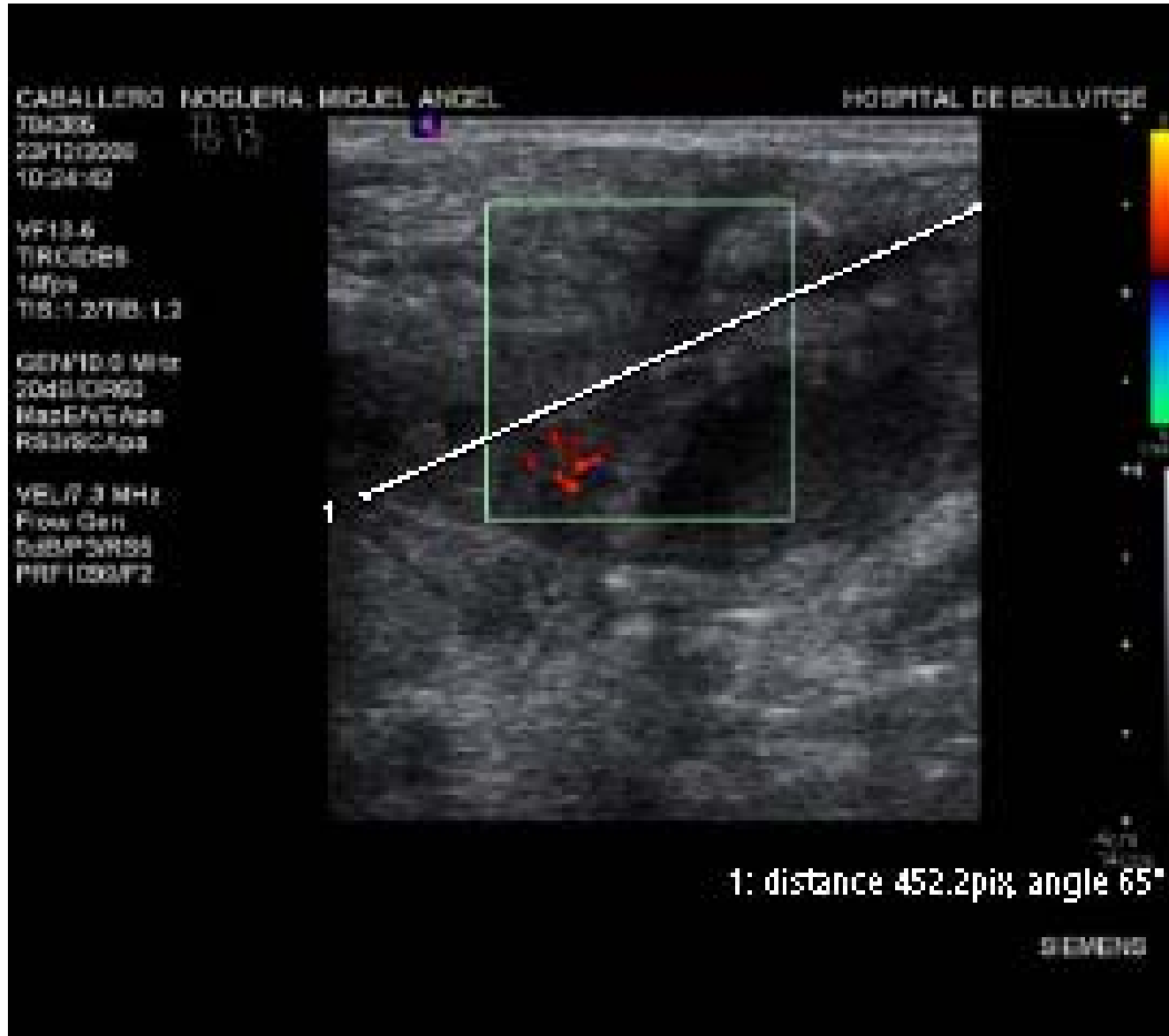- Case Record (16-2000) of the Mass. General Hospital. *NEJM, 2000; 342: 1590-1598*
- A 21-year-old male with productive cough, hemoptysis, chest pain and weight loss. *Respiration 2007; 74: 706-709*
- Hodgkin's disease mimicking suppurative lymphadenitis: a fine-needle aspiration report of five cases. *Vicandi et al. Diagn Cytopathol. 1999; 20: 302-306*
- Hodgkin's disease presenting with multiple cervical sinuses and abscess formation. *El-Tayeb Ali A. et al. Annals of Saudi Medicine 1999; 19: 350-351*

Hodgkin's lymphoma mimicking a suppurative disorder

- Hodgkin's disease presenting as liver abscesses.
Zaman A. et al. Gut 1991;32:959-962
- An unusual presentation of Hodgkin's lymphoma as a chest wall abscess in association with old tuberculosis. *Karimi S. et al. Tanafoss 2007;6:71-74*
- Hodgkin's lymphoma presenting as lung abscess.
Pickerill RG et al. Pennsylvania Medicine 1987;90:64-65
- Acute Hodgkin disease masquerading as splenic abscess. *Bloom RA. J Surg Oncol;1981;17:279-282*

Message: do not forget Hodgkin's in
"suppurative" lymphadenopathies

Other techniques can be helpful ? 



Lymphoma has hilar and peripheral uptake

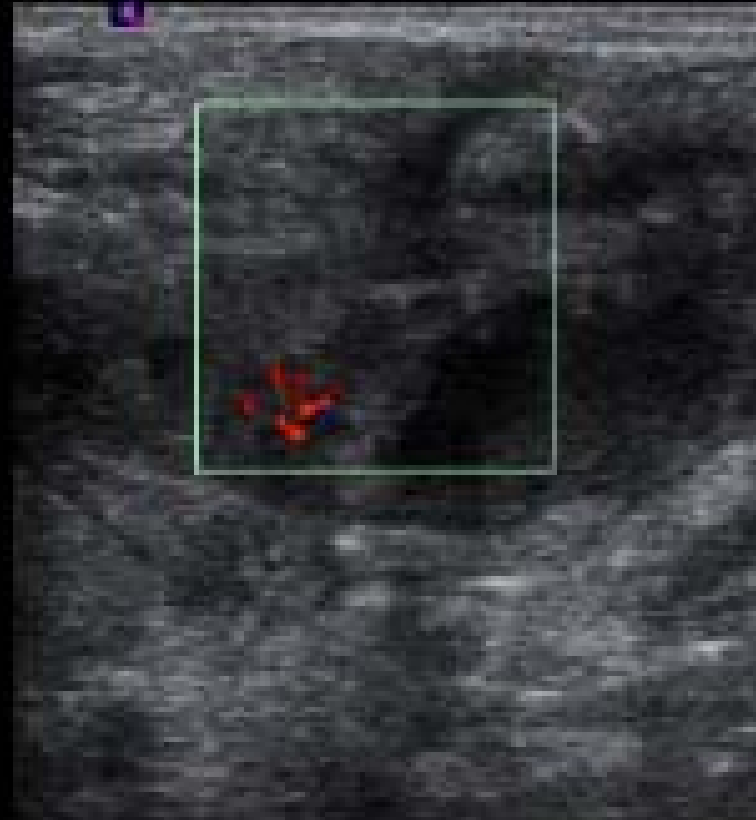CABALLERO NOGLERA MIGUEL ANGEL
T04306
23/12/2008
10:24:42

HOSPITAL DE BELLVITGE

VF13.6
TR08088
14fps
TIS:1.2/TIB:1.3

GEN10.0 MHz
2048 X 1090
MacEHC App
R63780 App

VEL17.0 MHz
Flow Gen
SubP3V155
PRF1000P2



4.0m
74cm

SIEMENS